Figurate Erythemas 19

Agustín España

Chapter Contents

Erythema Annulare Centrifugum 327
Erythema Marginatum 331
Erythema Migrans 333
Erythema Gyratum Repens 336

INTRODUCTION

Erythema represents a change in the color of the skin that is due to the dilation of blood vessels, especially those in the papillary and reticular dermis. The color, which is blanchable, can vary from pink to dark red to violaceous. Most erythemas last for days to months, but some may last only minutes (e.g. flushing). A very heterogeneous group of cutaneous disorders manifests as erythemas, ranging from palmar erythema of pregnancy to a diffuse scarlatiniform eruption. The erythemas discussed in this chapter all share a common feature – a figurate configuration.

In figurate erythemas, the lesions have an annular, arciform, or polycyclic appearance. While a wide range of cutaneous diseases can have an annular configuration (Table 19.1), there are four "classic" figurate erythemas: erythema annulare centrifugum, erythema marginatum, erythema migrans, and erythema gyratum repens.

ERYTHEMA ANNULARE CENTRIFUGUM

Synonyms: ■ Superficial or deep gyrate erythema ■ Erythema perstans ■ Palpable migrating (arciform) erythema

Key features

- Erythematous annular lesions that migrate centrifugally
- Superficial lesions can have the classic "trailing" white scale, while the deep gyrate erythemas have a more infiltrated border
- The disorder occurs more commonly in adults, and superficial lesions favor the thighs and hips
- Individual lesions usually last for several days to a few months
- Although often idiopathic in nature, it can be associated with infections (e.g. tinea pedis) and anecdotally with other disorders or exposures

Introduction

The term "erythema annulare centrifugum" (EAC) has come to encompass more than just annular erythematous plaques with trailing scale. One explanation for this is that once the other three major figurate erythemas (with specific etiologies; see below) and the disorders listed in Table 19.1 are excluded, EAC often becomes a "default" diagnosis. Unfortunately, this has led to some confusion, but until a specific "trigger" can be identified for each individual patient, this situation will persist. As a consequence, some authors have come to the conclusion that EAC, especially the deeper form, represents a clinical reaction pattern rather than a specific clinicopathologic entity[1]. Adding to the confusion is the school of thought in which the term EAC is reserved for only the superficial form.

History

In 1881, Colcott-Fox described persistent, ring-shaped lesions with pruritus, to which he gave the name "erythema gyratum perstans". The term "EAC" was introduced by Darier in 1916 while the name "erythema perstans" has been used by some authors to describe similar annular erythemas. It is now thought that all of these terms refer to clinical or pathologic variants of the entity now referred to as EAC[2]. However, Ackerman[3] preferred to call the two histologically different forms (superficial and deep) of EAC "superficial gyrate erythema" and "deep gyrate erythema", while Weyers et al.[4] believed that the superficial and deep forms of EAC were unrelated to one another and should not be referred to by the same name. These latter authors recommended that the term EAC be reserved for the superficial type, which in their opinion represented a specific clinicopathologic entity.

Epidemiology

Although EAC can appear in any age group, its peak incidence is in the fifth decade of life. There is no known sex difference. A rare autosomal dominantly inherited form of EAC, referred to as "familial annular erythema", has also been described[5].

Pathogenesis

It has been suggested that EAC, especially the superficial form with epidermal spongiosis histologically, represents a reaction pattern or "hypersensitivity" to one of many antigens[6]. EAC has been associated with infectious agents, particularly dermatophytes, but also with other fungi (e.g. *Candida*, *Penicillium* in blue cheese), viruses (e.g. poxvirus, EBV, varicella–zoster virus, HIV), bacteria (e.g. *Pseudomonas*, post-tonsillitis), parasites, and ectoparasites (e.g. *Phthirus pubis*). Less commonly, EAC has been linked to drugs (e.g. diuretics, nonsteroidal anti-inflammatory drugs, antimalarials, finasteride, amitriptyline, nivolumab, sorafenib, rituximab, pegylated interferon-α-2a plus ribavirin, ustekinumab [often as single case reports]), Crohn disease, pregnancy, autoimmune endocrinopathies, hypereosinophilic syndrome and, occasionally, neoplasms (e.g. lymphomas, leukemias, solid organ malignancies). The latter has been referred to as *p*araneoplastic *EAC e*ruption (PEACE)[7]. However, most of these associations are anecdotal, and, in the last group, Curth's postulates have not been consistently fulfilled (see Ch. 53). There are patients with EAC who noted resolution of their lesions after the diseases that presumably triggered the EAC were successfully treated. In one series, an associated disease was identified in only one-third of patients[8].

The peripheral migration of EAC lesions is thought to reflect localized production of proinflammatory cytokines and vasoactive peptides[9], but the precise mechanism is unknown.

Clinical Features

The initial lesions of EAC begin as firm pink papules that expand centrifugally and then develop central clearing. An individual lesion can enlarge to greater than 6 cm in diameter over a period of 1 to 2 weeks. If expansion of the annular plaque is not uniform, incomplete arcs appear, as do polycyclic lesions, or simply festooned bands. In the *superficial* form, the lesions are minimally elevated, and there is desquamation at the inner margin, i.e. trailing scale (Fig. 19.1A,B). The scale may not be present in all the lesions in a particular patient (Fig. 19.2A). There may be associated pruritus, especially in lesions that histologically show spongiosis.

Downloaded for Anonymous User (n/a) at Egyptian Knowledge Bank from ClinicalKey.com by Elsevier on March 10, 2024. For personal use only. No other uses without permission. Copyright ©2024. Elsevier Inc. All rights reserved.

DIFFERENTIAL DIAGNOSIS OF FIGURATE ERYTHEMA			
Disorders	**Clinical features**	**Histopathologic findings**	**Cross references**
Transient individual lesions (typically lasting <24 hours)			
Urticaria	Transient and recurrent wheals; pruritus	Dermal edema with sparse perivascular infiltrate of eosinophils and lymphocytes; occasionally neutrophils	Ch. 18
Urticaria multiforme (a variant of annular urticaria)	Annular and polycyclic wheals, often with central ecchymosis that should not be confused with necrosis; pruritus; edema of the face, hands, feet; absence of mucous membrane erosions or crusts; recent viral or bacterial infection	Indistinguishable from other forms of urticaria	
Serum sickness-like reaction	Annular and polycyclic wheals often have a purpuric component; acral edema; high fevers, arthralgias, lymphadenopathy; drug exposure (e.g. cefaclor, penicillins, minocycline)	Similar to urticaria; unlike serum sickness (e.g. due to equine- or rabbit-derived antithymocyte globulin), leukocytoclastic vasculitis is usually absent	
Erythema marginatum	Polycyclic erythematous eruption; antecedent group A streptococcal infection; additional manifestations of acute rheumatic fever, e.g. arthritis and carditis	Superficial perivascular infiltrate of neutrophils and lymphocytes; occasionally eosinophils	See text
Erythema marginatum-like lesions of hereditary angioedema	Transient polycyclic erythematous eruption; favors trunk; precedes or accompanies episodes of angioedema	Minimal to no inflammatory infiltrate	Ch. 18
African trypanosomiasis	Annular erythematous patches on the trunk associated with fever spikes	Perivascular lymphocytic infiltrate with many plasma cells; parasites are occasionally seen within the dermis	Ch. 83
Erythrokeratodermia variabilis et progressiva	Transient gyrate or circinate erythematous patches (usually fade/migrate within a few hours); also fixed figurate hyperkeratotic plaques; *GJB3, GJB4* > *GJA1* mutations	Scant perivascular lymphocytic infiltrate; dilated capillaries; psoriasiform acanthosis and mild hyperkeratosis (fixed plaques)	Ch. 57
Urticarial lesions lasting >24 hours			
Allergic urticarial eruption	Annular edematous plaques; favors trunk	Edema; superficial and deep lymphocytic infiltrate with eosinophils	
Wells syndrome	Edematous erythematous plaques, often annular or arcuate with a greenish color centrally; pruritus; peripheral eosinophilia	Diffuse infiltrate of eosinophils; flame figures	Ch. 26
Eosinophilic annular erythema	Recurrent annular edematous erythematous plaques; pruritus; some authors view as a subtype of Wells syndrome but peripheral eosinophilia is typically absent; originally described in children where overlap with eosinophilic form of annular erythema of infancy	Superficial and deep perivascular, periadnexal and interstitial lymphohistiocytic infiltrate with abundant eosinophils	
Annular erythema of infancy (including neutrophilic figurate erythema of infancy)	Recurrent annular erythematous plaques, usually lasting a few days; typically affects infants 3–11 months of age (see Fig. 19.4A); neutrophilic form can have purpura and vesicles and affect adults (see Fig. 19.4B)	Perivascular lymphocytes and eosinophils; sometimes a predominantly neutrophilic infiltrate	
Urticarial vasculitis	Urticarial plaques, often annular, that may have a purpuric or petechial component; pain, burning, and/or pruritus; systemic manifestations, especially in hypocomplementemic form	Leukocytoclastic vasculitis	Ch. 24
Erythema migrans	Erythema slowly migrates from site of tick bite; influenza-like syndrome; secondary distant lesions	Superficial and deep perivascular lymphohistiocytic infiltrate; eosinophils and plasma cells in some cases of erythema migrans; mucin and clusters of CD123+ plasmacytoid dendritic cells in LE tumidus; mucin in annular erythema of Sjögren syndrome	See text and Ch. 74
Erythema annulare centrifugum (deep)	Annular erythema with raised borders		See text
Lymphocytic infiltrate of Jessner	Annular erythematous plaques; favors face and upper trunk		Ch. 121
LE tumidus	Annular erythematous plaques; favors face, upper trunk > extensor forearms		Ch. 41
Annular erythema of Sjögren syndrome*	Annular erythematous plaques; favors face, arms, upper trunk; most common in Asian patients; anti-Ro antibodies		Ch. 45
Granulomatous lesions			
Granuloma annulare	Skin-colored to pink annular and arcuate plaques with borders composed of multiple papules; favors acral and extensor sites	Palisading granulomas with altered collagen and mucin	Ch. 93
Annular elastolytic giant cell granuloma	Pink annular plaques with atrophy and hypopigmentation centrally; favors sites of chronic sun exposure	Granulomatous infiltrate with elastophagocytosis by giant cells (border of lesion); absence of elastic fibers (center of lesion)	Ch. 93
Interstitial granulomatous dermatitis (IGD); interstitial granulomatous drug reaction (IGDR) (also referred to as reactive granulomatous dermatitis)	Annular erythematous plaques (or, in IGD, linear cords); favors axillae, groin, lateral trunk and legs; associated arthralgia/arthritis; IGDR is most often due to antihypertensive and lipid-lowering medications	Interstitial infiltrate of histiocytes with "rosetting" around collagen fibers and histiocytes surrounding single fibers of collagen; eosinophils may be present in IGDR	Ch. 93

Table 19.1 Differential diagnosis of figurate erythema.

Downloaded for Anonymous User (n/a) at Egyptian Knowledge Bank from ClinicalKey.com by Elsevier on March 10, 2024. For personal use only. No other uses without permission. Copyright ©2024. Elsevier Inc. All rights reserved.

DIFFERENTIAL DIAGNOSIS OF FIGURATE ERYTHEMA			
Disorders	**Clinical features**	**Histopathologic findings**	**Cross references**
Sarcoidosis	Red-brown annular plaques and papules; favors face; systemic manifestations	Sarcoidal granulomas ("naked tubercles")	Ch. 93
Borderline or tuberculoid leprosy	Annular plaques with raised erythematous borders and (in tuberculoid lesions) central hypopigmentation; asymmetric distribution; hypoesthesia, alopecia	Non-caseating granulomas with fragmentation of nerve fibers (tuberculoid leprosy); less well-defined granulomas (borderline leprosy)	Ch. 75
Papulosquamous lesions			
Erythema annulare centrifugum (superficial)	Annular lesions with trailing scale; favors thighs, hips and trunk	Superficial perivascular lymphocytes with focal spongiosis and parakeratosis; focal hemorrhage and exocytosis of lymphocytes in pityriasis rosea	See text
Erythema gyratum repens	Concentric erythematous rings with wood-grain appearance; erythema moves ~1 cm per day; associated with cancer		See text and Ch. 53
Pityriasis rosea	Herald patch on trunk; oval annular papules and plaques with central fine scaling and/or a collarette of trailing scale; Christmas-tree distribution on posterior trunk		Ch. 9
Pityriasis rubra pilaris	Appears as the primary "classic" lesions resolve; resembles erythema gyratum repens	Epithelial hyperplasia; alternating vertical and horizontal ortho- and parakeratosis; follicular plugging with shoulders of parakeratosis	See text and Ch. 9
Tinea corporis	Annular plaques with scale (exception: tinea incognito); pustules in border; concentric lesions in tinea imbricata; KOH-positive	Dermatophytes in the stratum corneum	Ch. 77
Lichen planus (LP), annular and actinic variants	Violaceous annular plaques; gray-brown to brown hyperpigmentation centrally; mucosal involvement; photodistribution in actinic LP	Hypergranulosis, band-like lymphocytic infiltrate at dermal–epidermal junction, necrotic keratinocytes	Ch. 11
Annular LE (subacute > discoid), *neonatal LE*, mothers of boys with chronic granulomatous disease	Photosensitivity; favors face (discoid), extensor upper extremities/upper trunk (SCLE), periorbital area (neonatal LE); anti-Ro antibodies (SCLE, neonatal LE); erythema gyratum atrophicans transiens neonatale is considered a variant of neonatal LE	Vacuolar interface dermatitis; variably dense periadnexal lymphohistiocytic inflammation with clusters of CD123+ plasmacytoid dendritic cells	Ch. 41
Seborrheic dermatitis	Erythematous annular plaques with scaling; favors face and central chest	Psoriasiform epithelial hyperplasia, spongiosis, perivascular lymphocytes	Ch. 13
Psoriasis	Annular scaly plaques with slow expansion	Psoriasiform epithelial hyperplasia, parakeratosis, diminished granular layer, elongated rete ridges, neutrophils migrating into epidermis	Ch. 8
Ichthyosis linearis circumflexa of Netherton syndrome	Serpiginous or circinate erythematous plaques bordered by double-edged scale; trichorrhexis invaginata; atopic diathesis, elevated serum IgE	Psoriasiform features with hyperkeratosis and a well-developed granular layer	Ch. 57
Lesions with absence or variable presence of scale			
Annular lichenoid dermatitis of youth	Red-brown annular patches or thin plaques with central hypopigmentation; favors groin and flanks; affects children and young adults	Lichenoid infiltrate; marked keratinocyte necrosis limited to the tips of rete ridges	Ch. 11
Erythema papulatum centrifugum	Usually a single, large annulus on the trunk whose border is 2–6 cm in width and composed of small erythematous papules, papulovesicles or crusted papules; favors Japanese men	Mononuclear infiltrate around eccrine ducts within the epidermis and dermis; spongiosis	
Secondary syphilis	Annular plaques with central hyperpigmentation; favors face; influenza-like symptoms; additional mucocutaneous manifestations; positive for RPR and FTA-ABS	Perivascular and interstitial infiltrate with plasma cells; also lichenoid or granulomatous infiltrate, exocytosis; bacilli can be identified by immunohistochemistry	Ch. 82
Mycosis fungoides	Annular erythematous or hypopigmented plaques, some with scale; admixed with classic lesions; often pruritic	Band-like infiltrate of lymphocytes in the papillary dermis with epidermotropism	Ch. 120
Neutrophilic sebaceous adenitis	Annular, indurated, erythematous plaques that favor the face and upper trunk of young adults; may be exacerbated by sun exposure	Focal necrosis of sebocytes; neutrophils within sebaceous glands; superficial and deep lymphocytic infiltrate	Ch. 25
Pustular lesions			
Pustular psoriasis (annular pattern)	Rapid expansion with erythematous borders studded with pustules	Subcorneal and spongiform pustules; neutrophils in the epidermis	Ch. 8
Sneddon–Wilkinson disease, IgA pemphigus	Pustules in a circinate pattern; peripheral expansion with central clearing; axillae, groin, inframammary areas	Subcorneal pustules; neutrophils in the epidermis; intercellular epidermal IgA deposition in IgA pemphigus	Chs. 8 & 29
Eosinophilic pustular folliculitis (Ofuji disease)	Grouped follicular pustules and papulopustules in an annular or serpiginous configuration; favors the face, trunk and arms	Infundibular eosinophilic pustules	Ch. 38

Table 19.1 Differential diagnosis of figurate erythema.

Continued

Downloaded for Anonymous User (n/a) at Egyptian Knowledge Bank from ClinicalKey.com by Elsevier on March 10, 2024. For personal use only. No other uses without permission. Copyright ©2024. Elsevier Inc. All rights reserved.

DIFFERENTIAL DIAGNOSIS OF FIGURATE ERYTHEMA			
Disorders	**Clinical features**	**Histopathologic findings**	**Cross references**
Erosive/vesiculobullous lesions			
Erythema multiforme (EM), Stevens–Johnson syndrome	Association with HSV and *Mycoplasma* vs drugs, respectively; target lesions more common in EM; mucosal involvement	Necrotic keratinocytes, vacuolar degeneration of the basal layer and variable inflammation	Ch. 20
Necrolytic migratory erythema	Erosion and crusting of advancing edge; periorificial involvement; glossitis; association with glucagonoma or liver/GI disorders (pseudoglucagonoma); constitutional symptoms	Pallor and edema of the upper epidermis; variable erosion	Ch. 53
Bullous pemphigoid, pemphigoid gestationis	Annular urticarial plaques; tense bullae; pruritus; peripheral eosinophilia	Subepidermal bullae with eosinophils > neutrophils; linear deposits of IgG and/or C3 in BMZ	Chs. 27 & 30
Linear IgA bullous dermatosis	Annular urticarial plaques; vesicles and bullae within border ("string of pearls"); pruritus	Subepidermal bullae with neutrophils > eosinophils; linear deposits of IgA in BMZ	Ch. 31
Epidermolysis bullosa simplex (especially generalized severe subtype [formerly Dowling–Meara subtype])	"Herpetiform" blisters in figurate array; episodic flares of migratory circinate erythema and blistering; *KRT5* or *KRT14* mutations	Intraepidermal split; eosinophilic inclusions within the keratinocytes	Ch. 32
Annular/cyclic epidermolytic ichthyosis	Migratory, annular or polycyclic, erythematous plaques with superficial blistering/peeling and scaling at the border; episodic flares; *KRT1* or *KRT10* mutations	Epidermolytic hyperkeratosis	Ch. 57
Purpuric lesions†			
Purpura annularis telangiectoides	"Cayenne pepper" petechiae and telangiectasias in annular configuration; favors trunk and legs	Capillary dilation and tight perivascular infiltrate of lymphocytes; extravasated erythrocytes; siderophages	Ch. 22
Acute hemorrhagic edema of infancy	Annular or targetoid, edematous, erythematous plaques that become purpuric; favors face, ears and extremities; febrile but non-toxic-appearing child <2 years of age	Leukocytoclastic vasculitis; perivascular IgA deposition in fewer than one-third of cases	Ch. 24
Perforating lesions‡			
Elastosis perforans serpiginosa	Peripheral edge composed of keratotic papules; favors neck and other flexural areas	Excess of degenerated elastic fibers in clumps in the superficial dermis with transepidermal elimination	Ch. 96

*Considered by some authors to be a form of SCLE.
†Purpura can also occur in urticarial vasculitis.
‡Giant variant of acquired perforating dermatosis can be annular.

Table 19.1 Differential diagnosis of figurate erythema. Key clinical features and histologic findings are provided. Disorders in *italics* favor children or childhood onset. Additional conditions that can present with figurate erythema include Kawasaki disease (may be erythema marginatum-like), hereditary periodic fever syndromes (especially *T*NF *r*eceptor-*a*ssociated *p*eriodic syndrome [TRAPS]; see Table 45.2), relapsing polychondritis, polymorphous light eruption, inflammatory vitiligo (including a papulosquamous variant), eosinophilic vasculitis, Sweet syndrome, neutrophilic eccrine hidradenitis, pyoderma vegetans (expanding pustular lesions), leukemia cutis, symmetric acral annular erythema, and porokeratosis. There is also an annular variant of acute generalized exanthematous pustulosis (e.g. due to terbinafine) and a generalized pustular figurate erythema associated with hydroxychloroquine. BMZ, basement membrane zone; FTA-ABS, fluorescent treponemal absorption; GI, gastrointestinal; LE, lupus erythematosus; RPR, rapid plasma reagin; SCLE, subacute cutaneous LE.

Occasionally, vesicles develop within the peripheral margin. In *deep* gyrate erythema, the advancing edges are obviously elevated (Fig. 19.1C) and there is usually no associated scale or pruritus.

As lesions resolve, there is no residual scarring, but postinflammatory hyperpigmentation can be seen and, on occasion, purpura. Although the lesions of EAC may be localized or generalized, they rarely, if ever, involve the palms, soles, scalp or mucous membranes. Individual lesions can persist for weeks to months, but associated systemic manifestations are uncommon. While new lesions can appear just as older ones resolve, there may be prolonged intervals of time between flares. Compared to the deep variant, the superficial form tends to recur more frequently but the individual lesions are often shorter-lived. The total duration of the disorder ranges from days to decades[2], and an unusual form of EAC has been described that recurs annually.

When EAC is due to an underlying disorder, flares of the former may correlate with recurrences of the latter. However, most patients with EAC do not have an identifiable underlying disorder, nor can the onset, fluctuations, or duration be related to a specific antigen.

Pathology

In *superficial* lesions of EAC, the findings are nonspecific, with mild spongiosis and microvesiculation plus associated focal parakeratosis, as well as a mild superficial perivascular lymphohistiocytic infiltrate. These histologic features correspond to the scale on the inner margin of the advancing erythematous arc. Characteristically, the inflammatory cells form a fairly tight aggregate around vessels, the so-called "coat sleeve" appearance (Fig. 19.1D). Rarely, eosinophils are found in the perivascular infiltrate. The advancing edge, which is slightly raised, may also show edema in the papillary dermis. The central area of clearing may contain dermal melanophages.

In *deep* lesions of EAC, the epidermis is usually unremarkable, and a mononuclear cell infiltrate with a sharply demarcated perivascular arrangement is present primarily within the mid and lower dermis. For this reason, the lesions are generally elevated and are more indurated than in the superficial form of EAC, and they do not have trailing scale.

Differential Diagnosis

EAC must be differentiated from other annular erythematous lesions (see Table 19.1)[10], particularly tinea corporis and annular psoriasis, when there is associated scale. Additional entities to consider include annular urticaria (Fig. 19.2B), allergic urticarial eruption, symmetric acral annular erythema, cutaneous lymphoid hyperplasia (pseudolymphoma), and lymphoma cutis. Patients with autoimmune disorders, including linear IgA bullous dermatosis, bullous pemphigoid, Sjögren

Downloaded for Anonymous User (n/a) at Egyptian Knowledge Bank from ClinicalKey.com by Elsevier on March 10, 2024. For personal use only. No other uses without permission. Copyright ©2024. Elsevier Inc. All rights reserved.

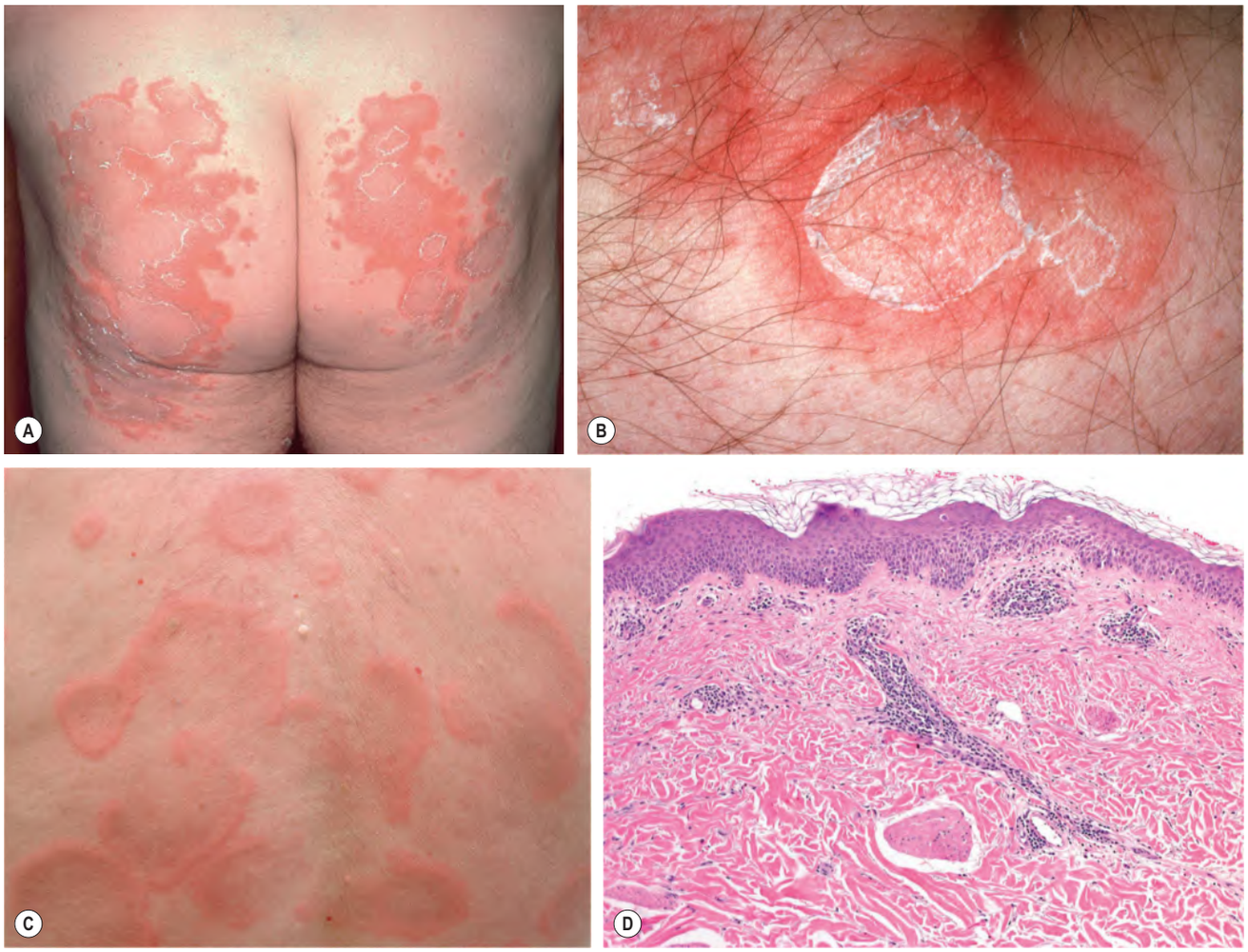

Fig. 19.1 Erythema annulare centrifugum. A, B Superficial form, with polycyclic plaque and delicate scale on the inner margin of the advancing edge (trailing scale). The scale is detached centrally. **C** Deep form, with obvious elevation of advancing edges and without trailing scale. **D** Photomicrograph of the superficial form with dermal perivascular lymphohistiocytic infiltrates; note the tight "coat sleeve"-like appearance of the infiltrate. *D, Courtesy Lorenzo Cerroni, MD.*

Fig. 19.2 A comparison of erythema annulare centrifugum and urticaria. The lesions in **A** have no scaling and may be confused with annular urticaria (**B**). However, individual lesions of urticaria are evanescent. Placement of an ink circle around a lesion, followed by longitudinal observation, allows this distinction.

syndrome, and lupus erythematosus (LE tumidus, subacute cutaneous LE, neonatal LE), can also have erythematous annular, arciform, and polycyclic lesions.

Treatment

If EAC is due to an underlying disorder, the skin lesions will usually resolve once the latter has been successfully treated. Topical corticosteroids applied to the advancing border of the lesions may be of benefit. Topical antipruritics and sedating antihistamines can be prescribed if there is associated pruritus. Even in the absence of an identifiable cause, some authors have advocated the empiric use of antibiotics (e.g. macrolides) or antifungal agents. Although systemic corticosteroids can induce a clinical remission, recurrences are common when the medication is discontinued. Based solely on case reports, the following have been reported as beneficial: topical tacrolimus, topical calcipotriene (calcipotriol), NB-UVB, oral metronidazole, apremilast, subcutaneous etanercept, and subcutaneous interferon-α. However, systemic therapies are seldom necessary.

ERYTHEMA MARGINATUM

Synonyms: ▪ Erythema marginatum rheumaticum ▪ Erythema annulare rheumaticum

Downloaded for Anonymous User (n/a) at Egyptian Knowledge Bank from ClinicalKey.com by Elsevier on March 10, 2024. For personal use only. No other uses without permission. Copyright ©2024. Elsevier Inc. All rights reserved.

Key features

- Migratory, annular and polycyclic, erythematous eruption
- Cutaneous manifestation of acute rheumatic fever
- Associated findings include carditis, migratory polyarthritis, Sydenham chorea, and subcutaneous nodules
- Seen more commonly in children than in adults

Introduction

Rheumatic fever (RF) is characterized by an abnormal immunologic response to a preceding infection with group A β-hemolytic streptococci and by the triad of fever, arthritis, and carditis. Cutaneous manifestations include erythema marginatum and subcutaneous nodules, but they are seen in a minority of patients. The diagnostic criteria of RF were recently revised in 2015 by the American Heart Association[11]: major criteria in low-risk populations are carditis or valvulitis (by echocardiography), polyarthritis, Sydenham chorea, erythema marginatum, and subcutaneous nodules. Minor criteria include fever, polyarthralgia, elevated acute phase reactants (ESR ≥60 mm, C-reactive protein ≥3 mg/dL), and prolonged PR interval on ECG. To establish the diagnosis of acute RF, two major or one major and two minor criteria must be accompanied by evidence of an antecedent group A streptococcal infection, e.g. a positive culture, an elevated or rising antistreptolysin O or anti-DNase B titer. In moderate- to high-risk populations, monoarticular arthritis is also considered a major criterion, with monoarthralgia and an ESR ≥30 mm representing additional minor criteria[11].

History

In 1831, Bright noted the presence of annular erythematous lesions in patients with RF. In 1889, Cheadle proposed the name "erythema marginatum rheumaticum"[12]. Carol and van Krieken first described the histopathologic findings in 1935. Two years later, Perry reported that rapid migration of the lesions was a characteristic finding[13]. In 1944, Jones established criteria for diagnosing RF[14].

Epidemiology

Attacks of acute RF are associated with antecedent group A β-hemolytic streptococcal infections of the pharynx. Approximately 3% of patients with untreated infections can develop acute RF. It is estimated that in high-income countries, i.e. low-risk populations, the incidence is 5 per 100 000, whereas in low-income countries, it ranges from 100 to 1000 per 100 000. Erythema marginatum is seen in less than 10% of patients with acute RF. The higher incidence of erythema marginatum in children (as compared to adults) reflects the predominance of RF during childhood; the peak age-related incidence is between 5 and 15 years[15].

Pathogenesis

The mechanisms that underlie erythema marginatum are unknown. Presumably, there is an abnormal humoral and cellular immune response to one or more antigens associated with group A β-hemolytic streptococci (e.g. M protein)[16]. Antigenic mimicry may play a role in that epitopes that cross-react with group A streptococcal antigens have been identified in human myosin, actin, tropomyosin, keratin, laminin, N-acetylglucosamine, and vimentin[17]. Specific characteristics of certain strains of group A β-hemolytic streptococci, such as higher M protein content and mucoid colony formation, may facilitate the development of acute RF[18]. Enhanced expression of genes that encode cysteine proteases (e.g. *Streptococcus pyogenes* exotoxin B [SpeB], immunoglobulin G degrading enzyme of *Str. pyogenes* [IdeS]) is thought to contribute to cardiotoxicity and virulence[19]. The role of host genetic factors is currently under investigation via genome-wide association studies[20].

Clinical Features

Following the initial episode of streptococcal pharyngitis, there is usually a latency period of 2–5 weeks before the development of the acute attack of RF. The lesions of *erythema marginatum* begin as erythematous macules that spread peripherally and become patches or plaques with no scale. Erythema marginatum can also have a polycyclic arrangement (Fig. 19.3). The lesions are usually asymptomatic, and, over a period of 12 hours, they can migrate from 2 to 12 mm; in areas of previous involvement, the skin may appear pale or lightly pigmented[15]. As with other erythemas, exposure to heat can accentuate lesions.

Fig. 19.3 Erythema marginatum. Polycyclic and evanescent annular lesions are seen on the trunk of this young patient.

The most common locations for erythema marginatum are the trunk, axillae and proximal extremities, with sparing of the face. New lesions usually last from a few hours to a few days and are often most noticeable during the afternoon. Recurrent crops can occur over a number of weeks. Erythema marginatum is associated primarily with the active phase of RF, and, in general, it is seen in conjunction with carditis. Of note, children less than 5 years of age appear to have a higher incidence of erythema marginatum as well as carditis and arthritis[21].

Subcutaneous nodules appear primarily over bony prominences, especially the wrists, elbows, knees and ankles, in patients with long-standing disease. The nodules are usually painless and are rare during the initial attack of RF. Similar nodules can be seen in patients with polyarticular juvenile idiopathic arthritis (see Ch. 45). In addition to the major and minor criteria (see above), patients may also have malaise, chest or abdominal pain, epistaxis, tachycardia and anemia, as well as a nonspecific urticarial eruption[18].

Pathology

An interstitial and perivascular infiltrate composed predominantly of neutrophils without vasculitis is observed. Occasionally, eosinophils are seen and in later stages, there can be extravasation of erythrocytes. Direct immunofluorescence microscopy for immunoglobulin and complement deposits is negative. These histologic findings are not unique to erythema marginatum, and overlapping features with the neutrophilic variant of annular erythema of infancy (neutrophilic figurate erythema of infancy) and the neutrophilic urticarial dermatosis seen in several autoinflammatory disorders may be observed.

Differential Diagnosis

The clinical differential diagnosis includes primarily annular urticaria (including urticaria multiforme) and annular erythema of infancy (Fig. 19.4A), as well as its variant neutrophilic figurate erythema of infancy[22]. Occasionally, neutrophilic figurate erythema is seen in adults and can be accompanied by vesicles and purpura (Fig. 19.4B). Less often, Still disease, hereditary periodic fever syndromes (particularly *T*NF *r*eceptor-*a*ssociated *p*eriodic *s*yndrome [TRAPS]; see Table 45.2), EAC, Kawasaki disease, and other entities listed in Table 19.1 need to be considered. Annular erythema with an appearance similar to erythema marginatum may precede or accompany episodes of hereditary angioedema[23] and is seen only occasionally in patients with cat scratch disease or psittacosis[24,25]. The angioedema-associated figurate erythema may be related to deposits of bradykinin within the dermis while the latter may reflect an overlap between erythema

Downloaded for Anonymous User (n/a) at Egyptian Knowledge Bank from ClinicalKey.com by Elsevier on March 10, 2024. For personal use only. No other uses without permission. Copyright ©2024. Elsevier Inc. All rights reserved.

Fig. 19.4 Annular erythema of infancy and neutrophilic figurate erythema. A Expanding annular urticarial plaques in a 6-month-old boy. Lesions are typically asymptomatic, expand slowly, and then resolve over a few days. New plaques may continue to appear for several months. **B** A neutrophilic variant occurs in both infants and adults and in the latter, there can be striking purpura within the lesions. *A, Courtesy Julie V. Schaffer, MD; B, Courtesy Lorenzo Cerroni, MD.*

marginatum and EAC. In a patient receiving sorafenib, figurate lesions with associated scale-crust and hemorrhage developed and the name "erythema marginatum hemorrhagicum" was proposed, but clinically these lesions can easily be distinguished from erythema marginatum[26].

Treatment

There is no specific therapy for this dermatosis. In general, its clinical course is unaltered by treatment of the underlying acute RF; however, symptoms are usually mild and lesions resolve spontaneously.

ERYTHEMA MIGRANS

Synonyms: ▪ Erythema chronicum migrans ▪ Lyme borreliosis (early stage) ▪ Lyme disease (early stage)

Key features

- Annular erythema develops at the site of the bite of a *Borrelia*-infected tick
- Several species of *Ixodes* ticks are infected with different genospecies of *Borrelia burgdorferi*
- Erythema migrans represents the initial cutaneous manifestation of Lyme disease and is seen in 60%–80% of patients diagnosed with the disease
- Multiple secondary lesions that may be smaller in size can occur as a result of spirochetemia or lymphatic spread

Introduction

Lyme disease (LD) is an infection due to *Borrelia burgdorferi* spirochetes that are transmitted by bites from several species of *Ixodes* ticks (e.g. *I. scapularis, I. pacificus, I. ricinus*; see Chs. 76 & 85). Erythema migrans represents the initial cutaneous manifestation.

History

The first report of an annular erythema developing after a tick bite was by Afzelius in 1909 and he coined the term "erythema migrans". Lipschütz then referred to these cutaneous lesions as "erythema chronicum migrans". In the US, Steere described an epidemic form of childhood arthritis preceded by erythema migrans in several communities in the vicinity of Lyme, Connecticut. In the 1980s, Burgdorfer isolated a new spirochete in lesions of erythema migrans and the organism was subsequently named *B. burgdorferi*[27].

Epidemiology

Although LD has a worldwide distribution, it is seen most commonly in the US (Northeast, mid-Atlantic, and Great Lakes regions) and in northern and eastern Europe. The competent hosts that serve as a reservoir for *Borrelia* include mice, chipmunks and birds, with deer playing a role in sustaining the life cycle[28]. In temperate regions, the peak incidence for LD is during the spring and the summer, and it occurs more commonly in those who spend time outdoors in or near fields and woods. Approximately 30 000 cases of Lyme disease are currently reported to the CDC each year, with 95% of confirmed cases coming from 14 states (www.cdc.gov/lyme/). Based upon recent US insurance claim data, an estimated 475 000 people were treated yearly for Lyme disease, but this number obviously includes noninfected individuals. In Europe, ~320 000 cases of LD are diagnosed each year, but the incidence varies depending upon the country[29,30]. Not all patients who have positive serologic tests for *B. burgdorferi* develop LD.

Pathogenesis

In mice, *B. burgdorferi* has been shown to usurp a tick salivary protein, Salp15, as a means of enhancing transmission[31]. By binding to the outer surface protein C (OspC) of *B. burgdorferi*, Salp15 provides protection against antibody-mediated killing. In addition, Salp15 inhibits adaptive immune responses against both *Borrelia* and tick antigens[32]. Of note, one of the proposed strategies for preventing LD is the development of anti-tick vaccines that utilize tick salivary proteins.

Once the *Borrelia* organisms have entered the body, spirochetal lipoproteins trigger an innate immune response, with cytokines being produced by macrophages[33]. In addition, a Th1 response is triggered and B cell responses facilitate the synthesis of antibodies against different antigens of *B. burgdorferi*. Spirochetemia is present in ~45% of patients at the time of their presentation with erythema migrans[34], and organisms can disseminate widely due to their ability to resist elimination by macrophages, evade complement, adhere to brain and epithelial cells, penetrate into the cytoplasm via intracellular junctions, and induce TNF production[35].

Even though the lesion expands centrifugally, *B. burgdorferi* organisms have been found both in the center and at the periphery of lesions

Downloaded for Anonymous User (n/a) at Egyptian Knowledge Bank from ClinicalKey.com by Elsevier on March 10, 2024. For personal use only. No other uses without permission. Copyright ©2024. Elsevier Inc. All rights reserved.

of erythema migrans. The persistence of the spirochete in the skin after the tick bite may be due to an absence of the production of interferon-γ and an ineffective immune response[33]. Also, different immune responses to the various genospecies of the *B. burgdorferi* sensu lato complex (*B. burgdorferi* sensu stricto, *B. afzelii*, *B. garinii*) may lead to different clinical presentations (e.g. borrelial lymphocytoma in Europe but not the US; see Ch. 74)[36]. More recently, an additional genospecies was identified in the upper midwestern US, *B. mayonii*, which may lead to a more severe clinical presentation due to an unusually high spirochetemia[37].

Clinical Features

LD is divided into three clinical stages: (1) early localized disease; (2) early disseminated disease; and (3) chronic disease (Table 19.2). Erythema migrans is an important clinical feature of early disease. Typically, 7–15 days (range, 3–30 days) after tick detachment, an erythematous, expanding, circular or annular plaque appears that may have a lighter-colored central area or a bull's-eye appearance (Fig. 19.5). The eventual diameter is usually at least 5 cm, and the center may become darker red to violaceous in color, crusted, or even vesicular. Lesions of primary erythema migrans favor the trunk, axilla, groin, and popliteal fossa. Untreated, the lesions usually last less than 6 weeks (median, 4 weeks). In 20%–25% of patients, multiple lesions can appear due to multiple tick bites or as a result of disseminated disease secondary to spirochetemia. Disseminated lesions tend to be smaller in size and less pronounced and usually appear days to weeks after the appearance of the primary erythema migrans (Fig. 19.6)[38].

Erythema migrans is seen in 60%–80% of patients diagnosed with LD. In the US, the systemic manifestations of this initial phase tend to be acute, with influenza-like symptoms, including fatigue, headache, arthralgia, myalgia and fever, as well as lymphadenopathy, conjunctivitis or hepatitis (see Table 19.2)[39]. In Europe, this initial clinical phase is usually less severe, and the lesions of erythema migrans tend to last longer. If untreated, ~60% of patients will go on to have monoarticular or oligoarticular arthritis (usually the knee) within weeks to months after the initial infection; ~10%, neurologic manifestations (most commonly facial nerve palsy); and ~5%, cardiac complications (usually varying degrees of atrioventricular block)[34]. For a discussion of borrelial lymphocytoma and acrodermatitis chronica atrophicans, see Chapter 74.

Depending upon the geographic region, *Ixodes* ticks can be co-infected with the following microbes (in addition to *B. burgdorferi*): *Babesia microti* (babesiosis)[40], *Anaplasma phagocytophilum* (anaplasmosis), *Borrelia miyamotoi*, or Powassan virus. Co-infections should be considered when patients with LD have prolonged or severe manifestations of infection, cytopenias, or an unusually high or persistent fever[28].

Pathology

The histologic features of erythema migrans are similar to those of a deep gyrate erythema (Fig. 19.7). While routine histology is often not specific, many specimens will show superficial and deep lymphoid infiltrates admixed with a few eosinophils and plasma cells. Immunohistochemical studies have shown a reduction in the number of Langerhans cells; in the dermis, the inflammatory infiltrate contains macrophages, $CD4^+$ T helper cells and $CD45RO^+$ memory T cells[41]. PCR analysis of tissue specimens can be performed to confirm the presence of *Borrelia* spirochetes within a lesion.

Differential Diagnosis

The 2022 revised CDC case definition for LD now includes three categories: "confirmed", "probable", and "suspected" (Table 19.3)[42]. These categories are based upon laboratory evidence and whether a person resides in a low-incidence versus high-incidence jurisdiction (state). Confirmatory laboratory evidence consists of one of the following: (1) isolation of *B. burgdorferi* sensu stricto or *B. mayonii* in culture; (2) detection of *B. burgdorferi* sensu stricto or *B. mayonii* in a clinical specimen by a *B. burgdorferi* group-specific nucleic acid amplification test (NAAT) assay; (3) detection of *B. burgdorferi* group-specific antigens by immunohistochemical assay on biopsy or autopsy tissues; or (4) positive serologic tests in a two-tier or equivalent format. The latter includes either: (1) the standard two-tier test (STTT) - a positive or equivocal first-tier screening assay, often an enzyme immunoassay (EIA) or immunofluorescence assay (IFA) for IgM, IgG or combination, followed by a concordant positive IgM or IgG immunoblot; or (2) modified two-tier test (MTTT) - positive or equivocal first-tier screen, followed by a different sequential positive or equivocal EIA in lieu of an immunoblot[42]. In 2019, the MTTT methodology was introduced in which an FDA-cleared second EIA (e.g. for VlsE1-IgG and pepC10-IgM) could be used in place of the Western immunoblot[44]. *Presumptive* laboratory evidence consists of a positive IgG immunoblot, interpreted by established criteria, without positive or equivocal first-tier screening.

Of note, the peak specific IgM response (usually directed against the 41 kDa flagellar antigen) occurs 3–6 weeks into the infection[35]. As a result, serologic testing has a low sensitivity, e.g. only 25%–40% of patients with erythema migrans during the acute phase (but without evidence of dissemination) have positive test results, with a slightly higher percentage in those with dissemination (~50%)[28]. During convalescence following antibiotic therapy, positive test results are still only observed in approximately half of those who did not have dissemination, presumably reflecting eradication of the spirochetes[28].

STAGES AND MAJOR ORGAN MANIFESTATIONS OF LYME DISEASE			
Organ	**Early localized disease**	**Early disseminated disease**	**Chronic disease**
Skin	Erythema migrans		Acrodermatitis chronica atrophicans (Europe)
	Disseminated erythema migrans Borrelial lymphocytoma (Europe)		
Nervous system		Lymphocytic meningitis Cranial neuritis Bell palsy Radiculoneuropathy	Encephalopathy Encephalomyelitis Neuropathy
Musculoskeletal system		Arthralgia, arthritis Myositis	Chronic arthritis
Heart		Atrioventricular block Myopericarditis, pancarditis	
Lymphatic	Regional lymphadenopathy	Regional or generalized lymphadenopathy	
Other		Conjunctivitis, iritis Hepatitis Non-productive cough Microscopic hematuria or proteinuria	

Table 19.2 Stages and major organ manifestations of Lyme disease. Patients with erythema migrans may also have influenza-like symptoms, including fatigue, headache, myalgia, and fever. *Adapted from Müllegger RR. Dermatological manifestations of Lyme borreliosis. Eur J Dermatol. 2004;14:296–309.*

Downloaded for Anonymous User (n/a) at Egyptian Knowledge Bank from ClinicalKey.com by Elsevier on March 10, 2024. For personal use only. No other uses without permission. Copyright ©2024. Elsevier Inc. All rights reserved.

Fig. 19.5 Erythema migrans. A, B Annular erythema that spreads centrifugally; the peripheral erythematous border may or may not be sharply demarcated and is usually 1–2 cm in width. Concentric rings can form, leading to a bull's-eye appearance, but some lesions of EM have a more uniform color. Vesiculation centrally can also be seen (**B**). **C** The center may become violaceous in color. Patients may not report a history of a tick bite. *A, Courtesy Department of Dermatology, Medical University of Graz; C, Courtesy Dennis Cooper, MD.*

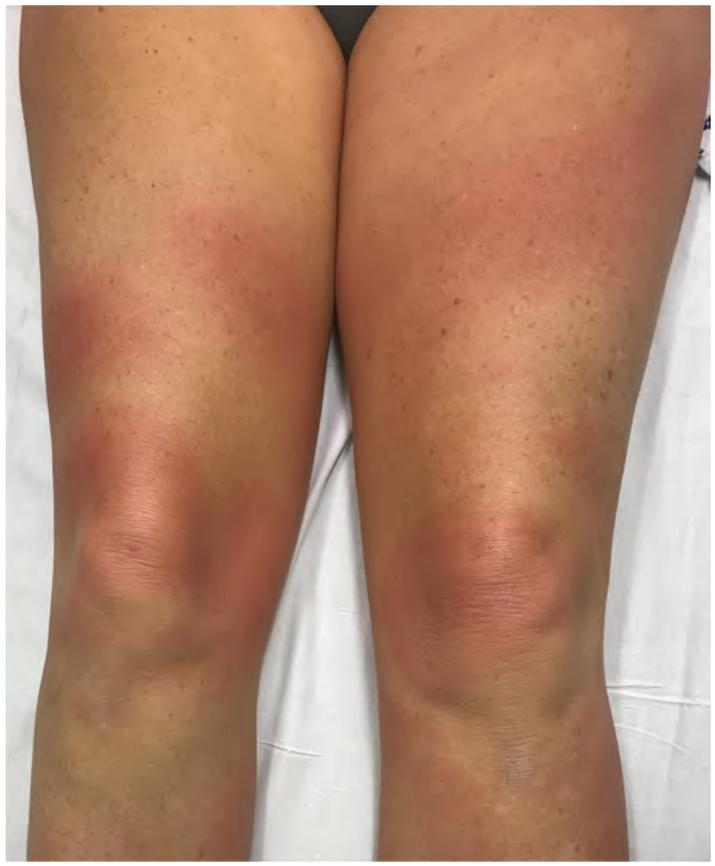

Fig. 19.6 Disseminated erythema migrans. Multiple pink circular and oval-shaped thin plaques with coalescence. Patients often have influenza-like symptoms. *Courtesy Ian W. Tattersall, MD, PhD.*

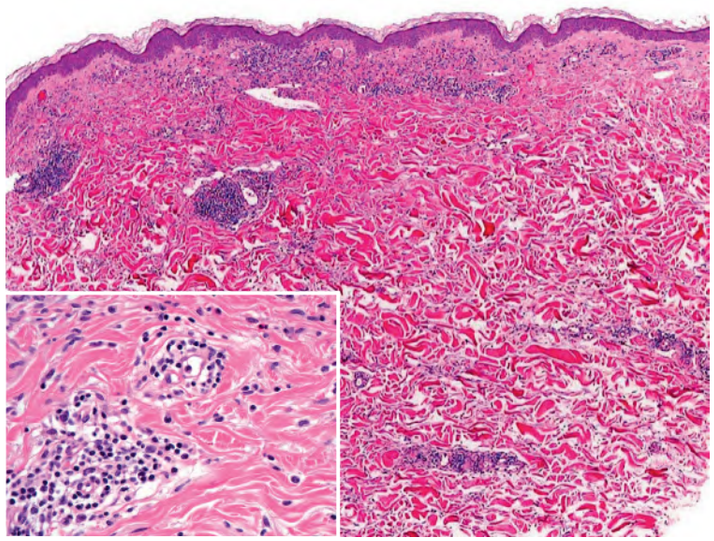

Fig. 19.7 Erythema migrans. A superficial and deep perivascular infiltrate is present within the dermis as well as a scattered interstitial pattern. The infiltrate is composed of lymphocytes and plasma cells (inset). *Courtesy Lorenzo Cerroni, MD.*

Although culture of tissue from the perimeter of erythema migrans lesions is essentially 100% specific and can distinguish live from dead organisms, it requires special agar (modified Barbour–Stoenner–Kelly medium) and prolonged observation, making it impractical in the standard clinical setting. As noted previously, detection of *B. burgdorferi* in skin biopsy specimens of erythema migrans via PCR is possible.

Erythema migrans must be distinguished from exaggerated local arthropod reactions (including to the tick bite), erysipelas, cellulitis, allergic contact dermatitis and non-pigmented fixed drug eruption, and less often, other entities outlined in Table 19.1. An erythema migrans-like skin lesion can be seen in southern tick-associated rash illness (STARI or Masters disease) which follows the bite of the lone star tick, *Amblyomma americanum* (see Ch. 85).

Downloaded for Anonymous User (n/a) at Egyptian Knowledge Bank from ClinicalKey.com by Elsevier on March 10, 2024. For personal use only. No other uses without permission. Copyright ©2024. Elsevier Inc. All rights reserved.

Treatment

Recommended antibiotic regimens are outlined in Table 19.4[43]. It is estimated that even in highly endemic areas, the risk of disease transmission from a recognized tick bite is low (1%–3%)[45]. This may be due to the observation that in general transmission from infected nymph ticks requires 36–48 hours of attachment and for adult ticks, ≥48 hours of attachment[28]. Therefore, routine treatment of tick bites with 2- to 3-week courses of antibiotics is not recommended. In patients from endemic areas (>20% of ticks infected) in whom the tick, identified as a nymphal or adult *I. scapularis*, has been attached for >36 hours and prophylaxis can be started within 72 hours of tick removal, a single 200 mg dose of doxycycline may decrease the risk of developing LD (from 3.2% in the placebo group to 0.4% in the treatment group in one study)[46].

ABRIDGED 2022 CDC LYME DISEASE SURVEILLANCE CASE DEFINITION
Definition of Erythema Migrans (EM)
A skin lesion that typically begins as a red macule or papule and expands over a period of days to weeks to form a large round lesion, often with partial central clearing. A single primary lesion must reach ≥5 cm in diameter. Secondary lesions also may occur. Annular erythematous lesions occurring within several hours of a tick bite represent hypersensitivity reactions and do not qualify as EM. EM may be accompanied by influenza-like symptoms (see text) and the diagnosis of EM must be made by a health care provider
Additional clinical criteria
• Recurrent, brief attacks of objective joint swelling in one or a few joints • Lymphocytic meningitis, cranial neuritis (particularly facial palsy [unilateral or bilateral]), radiculoneuropathy, or, rarely, encephalomyelitis • Acute onset of high-grade (2nd-degree or 3rd-degree) atrioventricular conduction defects that resolve in days to weeks and are sometimes associated with myocarditis
Laboratory criteria
• See text for details
Confirmed, probable, or suspect*
• High-incidence jurisdiction† - suspect if presumptive laboratory evidence • Low-incidence jurisdiction‡ - confirmed if confirmatory laboratory evidence and probable if presumptive laboratory evidence
*See website for details. †A jurisdiction with an average Lyme disease incidence of at least 10 confirmed cases/100 000 for the previous three reporting years [www.cdc.gov/lyme/stats/tables.html]. ‡A jurisdiction with an average Lyme disease incidence of <10 confirmed cases/100 000 for the previous three reporting years [www.cdc.gov/lyme/stats/tables.html].

Table 19.3 Abridged 2022 CDC Lyme disease surveillance case definition. CDC, Centers for Disease Control and Prevention. https://ndc.services.cdc.gov/case-definitions/lyme-disease-2022/

ERYTHEMA GYRATUM REPENS

Synonym: ■ Gammel disease

Key features

- A figurate erythema that is migratory and composed of concentric rings with a wood-grain appearance
- It represents a paraneoplastic phenomenon and the most common underlying neoplasm is carcinoma of the lung
- The lesions may have associated pruritus and scale, and they characteristically exhibit rapid migration (up to 1 cm per day)
- The cutaneous lesions resolve when the neoplasm is successfully treated

Introduction

In the vast majority of patients, erythema gyratum repens (EGR) represents a paraneoplastic figurate erythema. In theory, the cutaneous lesions arise as a result of an immune reaction against tumor-associated antigens with the subsequent recognition of similar antigens in the skin.

History

EGR was first reported by Gammel in 1952, and his original description clearly identified its key clinical features.

TREATMENT OPTIONS FOR LYME DISEASE				
Manifestation	**Drug**	**Dose (pediatric dose*)**	**Duration (days)**	**Comments**
Erythema migrans	Doxycycline	100 mg (2 mg/kg) po BID	14 (range, 10–21)	• Not preferred in children <8 yrs of age†, or pregnant or lactating women • Good CNS penetration • Also treats human granulocytic anaplasmosis
	Amoxicillin	500 mg (16 mg/kg) po TID	14 (range, 14–21)	
	Cefuroxime axetil	500 mg (15 mg/kg) po BID	14 (range, 14–21)	
	Azithromycin^	500 mg (10 mg/kg) po daily	7 (range, 5–10)	
Manifestation	**Drugs**		**Duration (days)**	**Comments**
Meningitis	Ceftriaxone (IV), cefotaxime (IV)		14 (range, 10–28)	
Cranial nerve palsy (without meningitis)	Same drugs and dosing as for erythema migrans		14 (range, 14–21)	• May not affect outcome of facial palsy
Carditis	If symptomatic, initiate treatment with parenteral antibiotic (e.g. ceftriaxone) then based upon clinical response, finish course with oral agents		14 (range, 14–21)	• Advanced heart block may require a pacemaker
Arthritis	Same parenteral agents as for meningitis and same oral agents as for erythema migrans		28	• If persists or recurs, a second course of antibiotics
*The maximum pediatric dose is the adult dose. †The American Academy of Pediatrics considers use of doxycycline for ≤21 days to be acceptable in children <8 years of age. ^For patients intolerant of both doxycycline and β-lactam antibiotics.				

Table 19.4 Treatment options for Lyme disease[43]. A Jarisch–Herxheimer-like reaction with an increase in systemic symptoms and in the size or intensity of the inflammation of the erythema migrans lesion occurs in ~15% of patients within 24 hours after the initiation of antimicrobial therapy. If all three antibiotics for erythema migrans are contraindicated, then macrolides (e.g. clarithromycin, erythromycin, azithromycin) can be prescribed but the cure rates are ~80% rather than 90% with recommended antibiotics[28]. BID, twice daily; IV, intravenous; po, orally; TID, three times daily; yrs, years.

Downloaded for Anonymous User (n/a) at Egyptian Knowledge Bank from ClinicalKey.com by Elsevier on March 10, 2024. For personal use only. No other uses without permission. Copyright ©2024. Elsevier Inc. All rights reserved.

Fig. 19.8 Erythema gyratum repens. Multiple gyrate erythematous plaques, showing a wood-grain pattern. *Courtesy Agustin Alomar, MD.*

Epidemiology

EGR is a very rare disorder seen primarily in adults. Risk factors parallel those for the underlying neoplasms.

Pathogenesis

A leading hypothesis is that EGR represents an immune reaction in which there is a cross-reaction between tumor and cutaneous antigens[47]. In a few patients, direct immunofluorescence (DIF) has demonstrated deposits of IgG and C3 in the basement membrane zone (BMZ) of the skin, and, in isolated cases, similar deposits were seen in the associated neoplasm[48]. However, this could simply represent a nonspecific finding. Caux et al.[48] suggested that the tumor produces a modification in its basement membrane and this subsequently induces an immune response. Recognition of similar antigens in the BMZ of the skin then leads to the cutaneous eruption. The responsible antigen(s) is not known, but a curious finding is an accumulation of active Langerhans cells in the upper layers of the epidermis[49]. Recently, a link between glutamine metabolism within the skin and the distinct pattern of EGR lesions was proposed[50].

Clinical Features

Patients usually have multiple, annular or polycyclic, erythematous lesions that develop scale at their edges and advance at a rapid rate (up to 1 cm per day)[51]. This rate of peripheral spread is significantly faster than that of EAC. Lesions have a wood-grain or zebra-like pattern, due to the development of "rings within rings" (Fig. 19.8). In some patients, the eruption is also pruritic. Additional findings in patients with EGR include acquired ichthyosis, palmoplantar keratoderma, and peripheral eosinophilia.

In at least 70% of patients, EGR is associated with an underlying neoplasm, most commonly of the lung then breast, esophagus or stomach[52]. The cutaneous lesions usually develop between 1 year prior to 1 year after the diagnosis of the neoplasm. EGR may coincide with underlying pulmonary tuberculosis, and patients with other disorders (see below) can also develop EGR-like lesions. Occasionally, no underlying disorder or malignancy can be identified.

Fig. 19.9 Resolving pityriasis rubra pilaris. The lesions can resemble erythema gyratum repens. *Courtesy Irwin Braverman, MD.*

Pathology

The histopathologic findings are nonspecific and include hyperkeratosis, focal parakeratosis, moderate patchy spongiosis and a mild, perivascular lymphohistiocytic infiltrate. In some cases, variable numbers of eosinophils are seen in the dermis.

Differential Diagnosis

In addition to excluding the other types of figurate erythema, EGR-like lesions may be seen in patients with erythrokeratodermia variabilis et progressiva and resolving pityriasis rubra pilaris (Fig. 19.9) as well as autoimmune bullous diseases, in particular bullous pemphigoid (both paraneoplastic and classic) and epidermolysis bullosa acquisita[52,53]. Similar appearing lesions can occasionally be seen in mycosis fungoides, resolving psoriasis, hypersensitivity reactions to azathioprine, urticarial vasculitis, and autoimmune connective tissue diseases, primarily lupus erythematosus (subacute variant [also referred to as LE gyratus repens] or an associated neutrophilic dermatosis or small vessel vasculitis), and Sjögren syndrome. In certain regions of the world (e.g. maritime and mainland Southeast Asia), tinea imbricata would also be included in the differential diagnosis.

Treatment

EGR resolves when the associated neoplasm is successfully treated. There may be a return of cutaneous lesions in association with the development of metastases or local recurrences of the malignancy.

Additional figures available in our eBook (see inside front cover for access code).

eFig. 19.1 Annular and arcuate urticaria. A, B Individual lesions of urticaria are evanescent.

eFig. 19.2 Erythema marginatum. Evanescent arciform and circular lesions can be clinically subtle. *Courtesy Eugene Mirrer, MD.*

eFig. 19.3 Erythema migrans. Annular erythema that spreads centrifugally. The peripheral erythematous border is usually 1–2 cm in width. Centrally, vesiculation is present.

eFig. 19.4 Erythema migrans. Two expanding circular pink plaques on the leg. *Courtesy Alicia Little, MD.*

Downloaded for Anonymous User (n/a) at Egyptian Knowledge Bank from ClinicalKey.com by Elsevier on March 10, 2024. For personal use only. No other uses without permission. Copyright ©2024. Elsevier Inc. All rights reserved.

eFig. 19.5 Disseminated erythema migrans. Multiple circular and a few annular plaques are scattered on the lower extremities as well as the trunk (not shown). *Courtesy Thomas Schwarz, MD.*

eFig. 19.6 Disseminated erythema migrans. Multiple circular pink plaques on the thigh and knee. Patients often have flu-like constitutional symptoms.

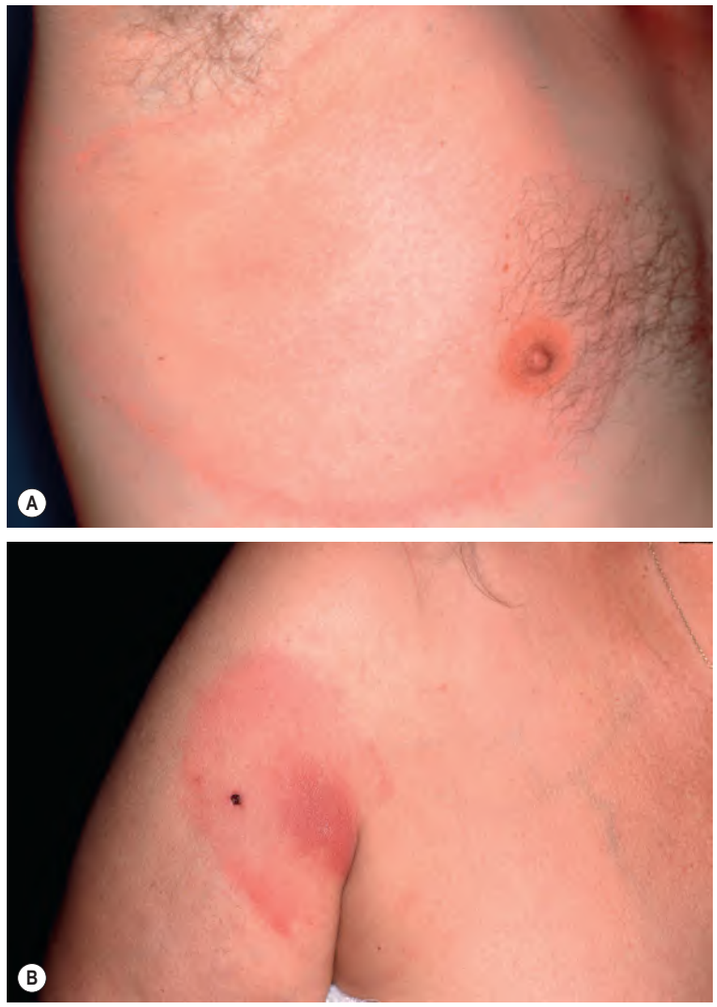

eFig. 19.7 Erythema migrans. A Annular erythema that spreads centrifugally; the peripheral erythematous border may or may not be sharply demarcated and is usually 1-2 cm in width. **B** Sometimes an arciform plaque is seen and the site of the tick bite may have more intense inflammation. A previous biopsy has been performed. *A, Courtesy Lorenzo Cerroni, MD; B, Courtesy Department of Dermatology, Medical University of Graz.*

eFig. 19.8 Eosinophilic annular erythema. Annular plaques on the lower extremities without secondary changes. Histopathologically, a dermal infiltrate of eosinophils is seen. Some authors view this entity as a subtype of Wells syndrome. *Courtesy Jonathan S. Leventhal, MD.*

Downloaded for Anonymous User (n/a) at Egyptian Knowledge Bank from ClinicalKey.com by Elsevier on March 10, 2024. For personal use only. No other uses without permission. Copyright ©2024. Elsevier Inc. All rights reserved.